



HIGH TIBIAL OSTEOTOMY

PATIENT INFORMATION

I would like to acknowledge doctors Mark McConkey, Sami Abdulmassiah and Annunziato Amendola for assembling this excellent information. I have edited the original material to make it more user-friendly for patients.

Introduction

High tibial osteotomy (HTO) has been used successfully to treat arthritis of the knee in symptomatic patients for many years. Arthritis of the knee joint is commonly localized to one compartment offering the potential to offload that compartment as a pain relieving treatment of the disease. Sagittal and coronal alignment directly affects distribution of force across the compartments of the knee and malalignment often accompanies unicompartmental knee arthritis leading to tissue overload and exacerbation of pain and joint degeneration. In simple terms, a bow-legged (VARUS) person will take excessive load in the medial compartment while a knock-kneed (VALGUS) person will take excessive load through the lateral compartment. Osteotomies are used to redirect weight-bearing forces across the knee joint for a number of reasons.

Currently, one of the most commonly employed HTOs is the valgus producing medial opening wedge osteotomy and will be the focus of this information sheet.

Indications & Contraindications

Patient characteristics that support a strong indication for an HTO include clinical and radiographic varus and (1) medial compartment arthrosis with or without mild to moderate asymptomatic radiographic patellofemoral arthrosis; (2) symptomatic ligamentous instability with medial compartment arthrosis; (3) recurrent ACL rupture with significant joint deformity; (4) medial compartment pain in the setting of total medial meniscectomy, osteochondritis dissecans or significant chondral damage (amendola 2).

Isolated medial sided degenerative joint disease with varus malalignment remains the most common indication for opening wedge HTO. The patient needs to be motivated and be aware that pain relief may not be complete or permanent. Patients under the age of 50 and with a body mass index (BMI) less than 25 are good candidates and demonstrate improved survivorship (Hui 10, Naudie 14). An HTO in a patient with an unstable knee and malalignment may improve pain and instability symptoms and potentially delay the onset of degeneration (Badhe 4, Naudie 13).

Activity levels are an important factor in determining if HTO is the best way to go. Under the age of 50, virtually all patients with malalignment and arthritis will be best served with an HTO (verses some type of joint replacement)

Absolute contraindications to HTO for medial compartment osteoarthritis include: inflammatory arthritis and significant lateral tibiofemoral joint disease. Poorer outcomes after HTO have been correlated with (1) severe articular destruction (Flecher 8), (2) significant patellofemoral disease (Rudan 18), (3) increased age (Gstottner 9, Naudie 14, Flecher 8), (4) lateral tibial thrust (Naudie 14), (5) decreased range of motion (Naudie 14) or (6) joint instability (Rudan 18). Recent literature presents evidence that ACL deficiency correlates with higher likelihood of long term survival suggesting that joint instability may not predict a poorer outcome (Hui 10). The preceding findings should be considered with each patient's clinical picture and serve as a basis to counsel each patient on the potential for a good functional outcome and should not be thought of as definitive reason to avoid performing an osteotomy.

Surgical Options

The two most common valgus producing HTOs performed are the medial opening wedge and lateral closing wedge osteotomies. Each has respective advantages and disadvantages which are briefly discussed below.

Medial opening wedge HTO has increased in popularity in recent years for a number of reasons. The theoretical advantages of employing an opening wedge osteotomy over a closing wedge procedure include (1) the usual deformity is proximal tibia vara, therefore the osteotomy directly addresses the anatomic deformity; (2) preservation of bone to the proximal tibia restores anatomy and potentially makes future arthroplasty procedures less technically challenging; (3) avoidance of disruption of the proximal tibiofibular joint and anterior compartment of the leg; (4) avoidance of the peroneal nerve; (5) requirement to make only one bone cut; (6) ability to modify the correction intra-operatively; (7) relative ease of combining the HTO with other procedures (e.g. ACL reconstruction, meniscal allograft).

The disadvantages of the medial sided procedure include (1) theoretical higher risk of nonunion due to the creation of a bony gap; (2) potential donor site morbidity if autograft is used or infectious disease transmission if allograft is used; (3) longer period of restricted weight bearing.

Less common surgical options available to modify the coronal and sagittal alignment of the proximal tibia include the dome osteotomy or gradual correction with an external fixator. These operations both offer the ability to correct large deformities that are not correctable by either opening or closing wedge techniques. These techniques are beyond the scope of this book chapter.

Radiographic Assessment

Radiographic assessment of an HTO candidate varies slightly depending on the indication for surgery. However, regardless of the indication all patients at the authors' institution will have 4 routine knee and 1 full length alignment film produced. The knee radiographs include bilateral anteroposterior weight-bearing films in full extension, bilateral posteroanterior weight-bearing films taken at 45 degrees of knee flexion, lateral and skyline views of the affected knee. In the patient with medial compartment osteoarthritis the radiographs are needed to assess the extent of the medial compartment osteoarthritis and to rule out extensive degeneration in the patellofemoral and lateral joint compartments. Other findings to note on the preoperative radiographs are the distal femoral and proximal tibial angles for deformity, sagittal tibial slope, lateral tibial subluxation and joint incongruency. On the full length radiograph, the weight-bearing axis is drawn from the center of the hip to the center of the ankle which determines where weight passes through the knee joint.

There are a number of potential methods that can be used to calculate the size of the osteotomy (coventry 5, dugdale 7, miniaci 12). The authors' currently employ the

method described by Dugdale et al (7) which corrects the weight-bearing axis to 62.5% of the width of the plateau or 3-5 degrees of mechanical valgus. An example of the calculation can be seen in Figure 1. If there is excess varus malalignment due to soft tissue laxity, the difference in congruency angle on the affected and unaffected legs noted on the bilateral standing full length AP radiograph is subtracted from the correction.

Surgical Technique

In many institutions a high tibial osteotomy is not a commonly performed procedure so the surgeon is responsible to ensure the operating room is set up appropriately and the implants are available. The surgeon needs to be familiar with the procedure, the instrumentation, and guide the surgery. Fluoroscopy is essential and a unit must be available and positioned appropriately in the operating room before starting the operation. A discussion should be undertaken with the patient and the anesthesia team regarding the risks and benefits of peripheral nerve blockade. Although some institutions perform HTOs as an outpatient procedure, it is significantly painful so the patient and hospital should be prepared for an overnight stay.

After general or spinal anesthesia has been given, the patient is positioned supine on a radiolucent table. Preoperative antibiotics are given within one hour prior to the start of the procedure. A thigh tourniquet is applied and all bony prominences well padded. Next the fluoroscopy unit is positioned in the room. If the surgeon chooses to use the large C-arm it should be positioned on the contralateral side of the patient to allow the surgical

team easy access to the limb at all times during the procedure. We prefer to use the small C-arm during an HTO. The leg can be abducted off the side of the bed and placed over the fluoroscopy unit which allows the use of a standard, non-radiolucent surgical bed. It also significantly decreases the radiation to which the surgical team is exposed.

A standard sterile preparation is completed and the leg is draped free. The planned incision and important bony landmarks are marked (Figure 2). A bump is placed under the knee to allow slight flexion and the tourniquet is inflated. If additional procedures are to be performed prior to the osteotomy (e.g. arthroscopy, ACL reconstruction, osteochondral allograft) the surgeon should consider waiting to inflate the tourniquet so as not to exhaust tourniquet time prior to the completion of the HTO. A longitudinal incision is made midway between the tibial tubercle and the posterior tibial metaphysis extending 6 centimeters (cm) distally from 1 cm inferior to the medial joint line. The cautery is used to dissect just medial to the patellar tendon and a retractor placed posterior to the tendon to protect it during the HTO. The superior 2-3 millimeters of tendon can be elevated from the tubercle if needed. The pes anserinus and superficial medial collateral ligament are raised as a single flap using cautery and a Cobb elevator. When the posterior tibial cortex is reached a retractor is carefully placed directly along the posterior tibial cortex (Figure 3).

A guide pin is drilled from the medial tibial cortex approximately 4 cm distal to the joint line towards the superior aspect of the proximal tibiofibular joint (Figure 4). Fluoroscopy is used to assess the position of the wire and then a corticotomy is made inferior to the

wire with a small oscillating saw (Figure 5). It is important to keep the wire superior to the osteotomy to shield the joint from intraarticular fracture. A thin, flexible AO osteotome is employed to begin the osteotomy and is tapped into place inferior to the wire medially, anteromedially and posteromedially using fluoroscopy to assess progress (Figure 6). Once the osteotome has been seated approximately 1 cm from the lateral cortex it is removed and the large stackable osteotome is tapped into place. Markings on the osteotomes allow the surgeon to gauge the depth of the osteotomy. Another osteotome is then 'stacked' inferior to the large osteotome until the medial cortex can be seen to hinge open. The large osteotome is used superiorly to once again protect the lateral joint from intraarticular fracture (Figure 7). The osteotomes are removed and the calibrated wedges are carefully tapped into place to the depth predetermined on the preoperative template. Again, fluoroscopy images are used to assess the depth and to ensure no intraarticular fracture has occurred (Figure 8). At this point an alignment guide or cautery cord can be used to assess the correction with the large C-arm. The authors feel that the error inherent in intraoperative assessment is large and prefer to rely on preoperative templating and intraoperative clinical assessment. The anterior wedge is removed allowing the plate with the appropriately sized wedge block to be inserted (Figure 9). The plate should be inserted as far posteriorly as possible in order to reduce the chance of increasing the posterior slope. The bump is now placed under the heel to allow full extension of the knee and extension through the osteotomy. The posterior slope is not significantly changed if the opening anteriorly is half the size of the opening posteriorly (Noyes 15). Screws are sequentially placed using fluoroscopy to ensure no hardware complications have occurred. It is debated whether small

corrections (< 7.5 mm) require bone graft or bone graft substitute. I typically do not use bone graft for corrections less than 10mm, and bone graft harvested from the iliac crest (prominence of the hip) for corrections 10mm or greater. The wound is thoroughly washed and closed in a standard fashion.

Navigation

Since 2009 I have used the Stryker computer navigation system. This is to achieve the most accurate post-op alignment possible. The two most common complications of HTO are over and under correction. Computer navigation has been shown to reduce the number of “outliers” where, for various reasons, correct alignment is not achieved. In simple terms we do this for greater accuracy and thus better results for the patient.

Two small guide pins are inserted into the tibia and two more into the femur. Points inside the hip, knee and ankle are registered. Special computer trackers are attached and a sensor in the operating room indicates precise alignment of the limb.

Rehabilitation

Patients undergoing an HTO are kept in hospital for one night and discharged home the following day. No brace is required. It is very important to keep the limb elevated for much of the first week. A quiet time around home is recommended with the leg raised on a pile of pillows. Minimising swelling is important. The patient is non-weight bearing with crutches for 6 weeks. We then arrange a clinic appointment where we review the new xray. If healing is progressing well, we wean off the crutches over the next 10

days. With smaller corrections (i.e. < 7.5 mm), earlier weight bearing may be initiated at the discretion of the surgeon. Active assisted range of motion is tolerated as well as straight leg raises and calf strengthening. At 8-12 weeks, if healing is progressing well, the patient is progressed to full weight bearing and advanced to aggressive strengthening with physical therapy. The patient should expect to walk without crutches within 8 weeks of surgery. Return to work is possible in 2-3 weeks if the patient works at a desk. Return to laboring work and sports activities is expected to be at approximately 3-4 months.

Results

The vast majority of the articles reporting long term results of HTO involve lateral closing wedge osteotomies often times treated with cylinder cast immobilization. Recent literature of long term results of HTO report good outcomes up to 20 years postoperatively (tang 19, papachristou 16, flecher 8, hui 10). In 2005, Tang and Henderson (19) reported survivorship of 74.7% at 10 years and 66.9% at 15 and 20 years in their cohort of patients treated with closing wedge HTO and fixed with a staple and a cast. After a similar procedure, Papachristou et al (16) reported 66% survival at 15 years and 53% survival at 17 years. Flecher et al (8) reported an 85% survivorship at 20 years in 301 patients following closing wedge HTO. In 2011, Hui et al (10) reported a retrospective review of 413 patients who had undergone closing wedge HTO. They reported 95%, 79% and 56% survival at 5, 10, and 15 years respectively, and 85% satisfaction rate.

Contemporary long term results of medial opening wedge HTOs in the literature are non-existent but some early and midterm results have been reported (Amendola 3, DeMeo 6). DeMeo et al (6) reported midterm survivorship of opening wedge HTO. They found Lysholm and HSS scores improved from 54.2 and 75.9 preoperatively to 89.1 and 92.7 at 2 years postoperatively, respectively. They also reported a survivorship of 70% at 8 years in a total of 20 patients.

Opening wedge HTO is increasingly used in combination with other procedures around the knee for diseases other than unicompartmental joint degeneration (i.e. revision ACL surgery, off-loading of osteoarticular or meniscal allografts, chronic posterolateral soft tissue laxity). For example, Naudie et al (13) performed 17 HTOs on 16 patients with symptomatic hyperextension varus thrust. At an average follow-up of 56 months, all patients had an improvement in their activity level postoperatively and 15 of 16 were satisfied and would undergo the procedure again. Overall, the results of HTO in these combined procedures are difficult to assess due to the complexity of the problem, the heterogeneity of the injury pattern and the combined nature of the surgery.

Conclusions

High tibial osteotomy is a valuable procedure in the arsenal of the modern knee surgeon. The most common indication is unicompartmental medial sided arthritis of the knee in a physiologically young person. The long term results of this procedure are not yet known but good long term outcomes out to 15-20 years have been demonstrated with closing wedge procedures. It should also be considered in other situations such as

to offload meniscal allografts, osteoarticular auto or allografts, and in patients with chronic soft tissue laxity and malalignment. The described surgical technique offers a reproducible procedure with several advantages over the closing wedge technique.

References

1. Akizuki S, Shibakawa A, Takizawa T, Yamazaki I, Horiuchi H. The long-term outcome of high tibial osteotomy: a ten- to 20-year follow-up. *J Bone Joint Surg Br.* 2008; 90: 592-596.
2. Amendola A, Bonasia DE. Results Of High Tibial Osteotomy: Review Of The Literature. *Int Orthop.* 2010; 34:155-160.
3. Amendola, A, Fowler, P, Litchfield, R, Kirkley S, Clatworthy, M. Opening Wedge High Tibial Osteotomy Using A Novel Technique: Early Results And Complications. *J Knee Surg.* 2004; 17: 170-5.
4. Badhe NP, Forster IW. High tibial osteotomy in knee instability: the rationale of treatment and early results. *Knee Surg Sports Traumatol Arthrosc.* 2002;10:38-43.
5. Coventry MB. Upper tibial osteotomy for osteoarthritis. *J Bone Joint Surg Am.* 1985; 67: 1136-40.

6. DeMeo PJ, Johnson EM, Chiang PP, Flamm AM, Miller MC. Midterm follow-up of opening-wedge high tibial osteotomy. *Am J Sports Med* 2010; 38: 2077-2084.
7. Dugdale TW, Noyes FR, Styer D. Preoperative planning for high tibial osteotomy: the effect of lateral tibiofemoral separation and tibiofemoral length. *Clin Orthop*. 1992: 248-64.
8. Flecher X, Parratte S, Aubaniac JM, Argenson JN. A 12-28-year followup study of closing wedge high tibial osteotomy. *Clin Orthop Relat Res* 2006; 452: 91-96.
9. Gstottner M, Pedross F, Liebensteiner M, Bach C. Long-term outcome after high tibial osteotomy. *Arch Orthop Trauma Surg* 2008; 128: 111-115.
10. Hui C, Salmon LJ, Kok A, Williams HA, Hockers N, van der Tempel WM, Chana R, Pinczewski LA. Long-term survival of high tibial osteotomy for medial compartment osteoarthritis of the knee. *Am J Sports Med*. 2011; 39: 64-70.
11. Koshino T, Yoshida T, Ara Y, Saito I, Saito T. Fifteen to twenty-eight years' follow-up results of high tibial valgus osteotomy for osteoarthritic knee. *Knee* 2004; 11: 439-444.
12. Minaci A, Ballmer FT, Ballmer PM, Jakob RP. Proximal tibial osteotomy: a new fixation device. *Clin Orthop*. 1989: 250-9.
13. Naudie DD, Amendola A, Fowler PJ. Opening wedge high tibial osteotomy for symptomatic hyperextension-varus thrust. *Am J Sports Med*. 2004; 32: 60-70.
14. Naudie D, Bourne RB, Rorabeck CH, Bourne TJ. Survivorship of the high tibial valgus osteotomy: A 10- to 22- year followup study. *Clin Orthop Relat Res* 1999; 367: 18-27.

15. Noyes FR, Goebel SX, West J. Opening wedge tibial osteotomy: the 3-triangle method to correct axial alignment and tibial slope. *Am J Sports Med* 2005; 33: 378-387.
16. Papachristou G, Plessas S, Sourlas J, Levidiotis C, Chronopoulos E, Papchristou C. Deterioration of long-term results following high tibial osteotomy in patients under 60 years of age. *Int Orthop* 2006; 30: 403-408.
17. Sprenger TR, Doerzbacher JF. Tibial osteotomy for the treatment of varus gonarthrosis. Survival and failure analysis to twenty-two years. *J Bone Joint Surg Am* 2003; 85-A: 469-474.
18. Rudan JF, Simurda MA. High tibial osteotomy. A prospective clinical and roentgenographic review. *Clin Orthop Relat Res* 1990; 255: 251-256.
19. Tang WC, Henderson IJP. High tibial osteotomy: long term survival analysis and patients' perspective. *Knee* 2005; 12: 410-413.

Tables

Surgical Steps:

Surgical Steps	
1. Preoperative Checklist	<ul style="list-style-type: none">• consent, antibiotics, tourniquet, fluoroscopy, radiolucent table, implants, company representative, bone graft or substitute
2. Incision	<ul style="list-style-type: none">• 6 cm, midway between tibial crest and posterior cortex• elevate pes anserinus and sMCL as single flap• retractors posterior to patellar tendon and along posterior tibial cortex
3. Osteotomy	<ul style="list-style-type: none">• guide pin is placed from medial tibial cortex towards superior aspect of tibiofibular joint• small oscillating saw for corticotomy <i>inferior</i> to guide pin• flexible osteotome under fluoroscopy guidance• wide Arthrex osteotome is tapped into place and narrower osteotome is 'stacked' inferior to it under fluoroscopy guidance, opening the osteotomy
4. Hardware Insertion	<ul style="list-style-type: none">• Graduated wedges are inserted to predetermined depth• Anterior wedge is removed and plate inserted• shaft screw is drilled and placed to attach plate to bone• knee is extended to decrease anterior opening in order to ensure no increase in slope• remainder of screws are placed and fluoroscopy checked• bone graft or substitute is placed if necessary
5. Closure	<ul style="list-style-type: none">• tourniquet deflation• thorough irrigation and hemostasis• reapproximation of pes anserinus over plate• skin closure• hinged knee brace

Chapter synopsis	High tibial osteotomy is a valuable procedure and, when appropriate indications and contraindications are followed has good outcomes reported in the literature. In this chapter, we will describe the surgical technique for opening medial wedge high tibial osteotomy (HTO).
Important points	<p>HTO changes both the coronal and the sagittal plane alignment. Medial opening wedge HTO has a tendency to increase the tibial slope whereas lateral closing wedge HTO has a tendency to decrease the tibial slope.</p> <p>Indications for HTO are varus limb alignment with:</p> <ul style="list-style-type: none"> • Unicompartmental medial sided arthritis in a physiologically young person • Chronic soft tissue laxity • Medial meniscal allograft transplantation procedure • Cartilage resurfacing procedure in the medial compartment
Clinical/surgical pearls	<ul style="list-style-type: none"> • The patient with isolated medial sided degenerative joint disease who is indicated for HTO should be highly active, motivated and be aware that pain relief may not be complete or permanent. • In the varus knee, slight overcorrection into valgus is encouraged. In most cases the preoperative template should aim to correct the mechanical axis to 62.5% of the width of the plateau. • Guide pin placement is critical: Do not accept anything less than optimum pin placement • The guide pin is inserted from the medial tibial cortex approximately 4 cm distal to the joint line towards the superior aspect of the proximal tibiofibular joint (passing just above the level of the tibial tubercle).
Clinical/ surgical pitfalls	<p>The tip of the guide pin should be far enough from the joint line (>1.5cm)</p> <p>Keep the guide pin in place while performing the osteotomy distal to it to prevent propagation of the osteotomy toward the joint line</p> <p>The beveled side of the AO osteotome should be away from the joint line</p> <p>The osteotomy should be perpendicular to the tibial shaft in the sagittal plane so that the plate would be aligned with and in good apposition with the proximal tibial metaphysis</p>
Video available	N/A

Authors	Year	Technique	Results
Naudie et al. 14	1999	Closing wedge, dome	75% at 5 yrs, 51% at 10 yrs, 39% at 15 yrs, 30% at 20 yrs
Sprenger and Doerzbacher 17	2003	Closing wedge	65-74% at 10 yrs
Koshino et al. 11	2004	Closing wedge	97.3% at 7 yrs, 95.1% at 10 yrs, 86.9% at 15 yrs
Tang and Henderson 19	2005	Closing wedge	89.5% at 5 yrs, 74.7% at 10 yrs, 66.9% at 15 and 20 yrs
Papachristou et al. 16	2006	Closing wedge	80% at 10 yrs, 66% at 15 yrs, 52.8% at 17 yrs
Flecher et al. 8	2006	Closing wedge	85% at 20 yrs
Gstottner et al. 9	2008	Closing wedge	94% at 5 yrs, 79.9% at 10 yrs, 65.5% at 15 yrs, 54.1% at 18 yrs
Akizuki et al. 1	2008	Closing wedge	97.6% at 10 yrs, 90.4% at 15 yrs
DeMeo et al. 6	2010	Opening wedge	70% at 8 yrs, Lysholm & HSS improved from 54.2 and 75.9 to 89.1 and 92.7 at 2 yrs
Hui et al. 10	2011	Closing wedge	95% at 5 yrs, 79% at 10 yrs, 56% at 15 yrs

Figure 1a: A long leg anteroposterior radiograph is used to template the osteotomy. Correction of the weightbearing axis is achieved to 62.5% of the medial to lateral plateau distance. A line is drawn from the center of the femoral head to the point on the plateau corresponding to the new weightbearing axis. Another line is drawn from the weightbearing axis to the center of the ankle joint. The angle formed by the intersection of these lines is the angle of the osteotomy.

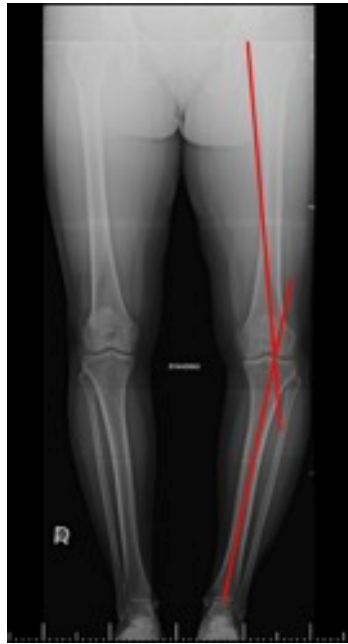

Figure 1b: To calculate the size of the osteotomy in millimeters the length of the osteotomy (blue arrows) is measured and overlaid onto the intersection of the weightbearing axis. The distance between the femoral and tibial weightbearing lines approximates the size of the osteotomy at the medial metaphysis.

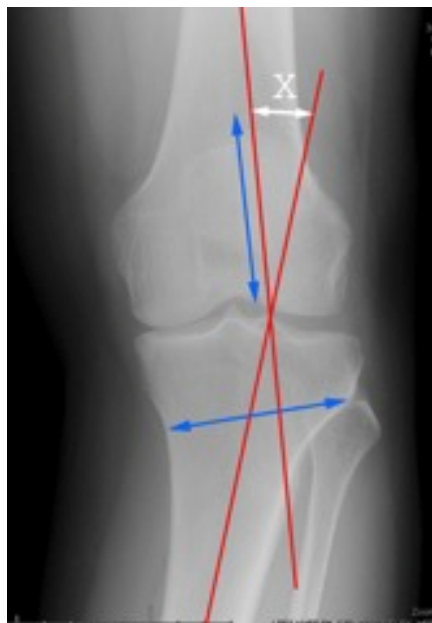

Figure 2: The patient is positioned supine with a bump under the knee to allow for knee flexion. Landmarks are drawn and the incision is taken from the medial joint line down distal to the tibial tubercle. The incision is halfway between the tubercle and the posteromedial tibial.

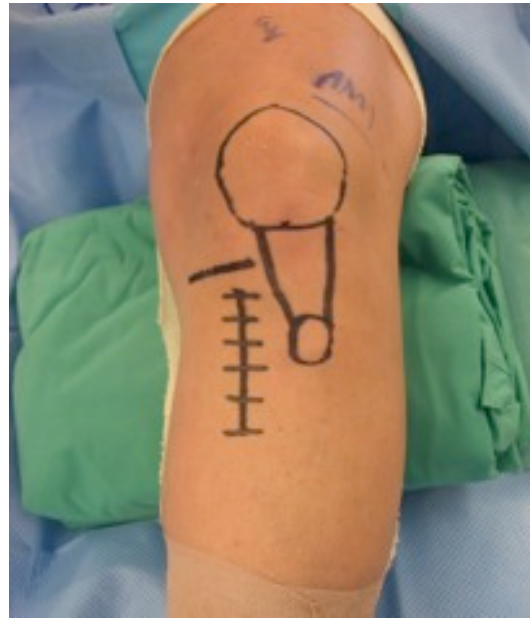

Figure 3: The incision is made and the medial soft tissues including pes anserinus and the superficial medial collateral ligament are raised as one full thickness flap. An Army- Navy retractor is placed under the patellar tendon and a Hohmann retractor along the posterior tibia.

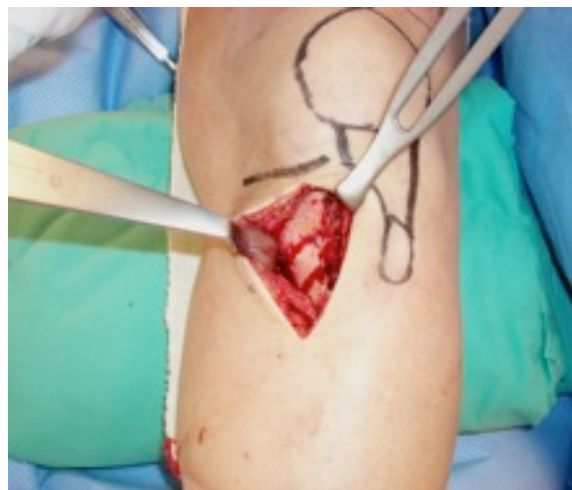

Figure 4a: A guidewire is placed from the medial tibial metaphysis approximately 4-5 cm distal to the joint line directed towards the superior aspect of the proximal tibiofibular joint. Care is taken to ensure the patellar tendon insertion is distal to the osteotomy site.

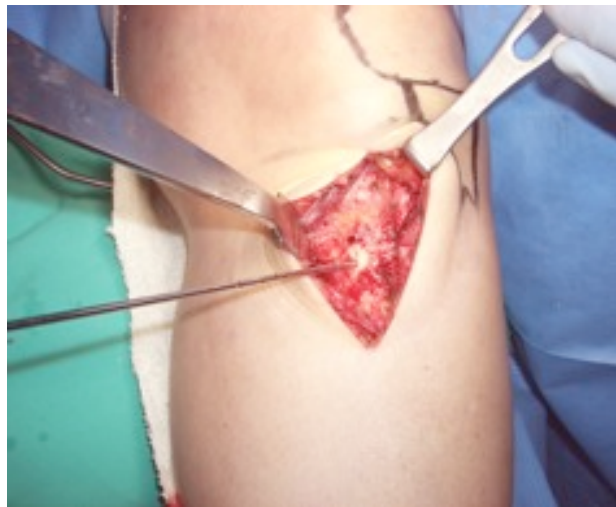


Figure 4b: Fluoroscopy is used to ensure the tip of the wire is 1 cm from the lateral cortex and 1.5-2 cm from the lateral tibial plateau.

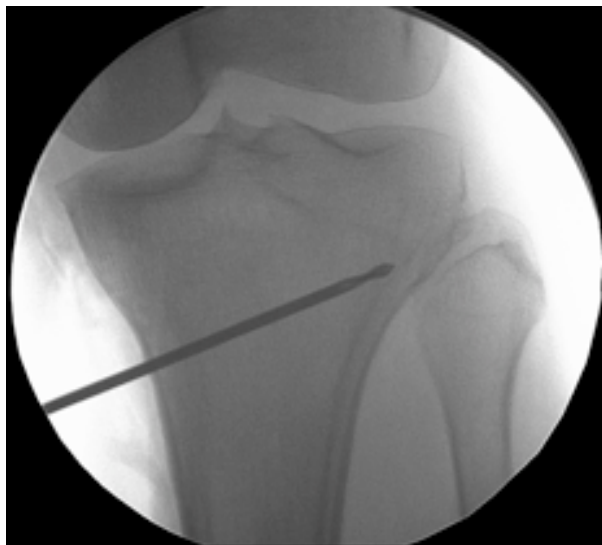

Figure 5: A corticotomy is made with an oscillating saw distal to the guidewire and the osteotomy started with a flexible osteotome. Attention is paid to ensure the osteotomy is proximal to the patellar tendon insertion. Fluoroscopy is used to monitor the progression of the osteotomy.

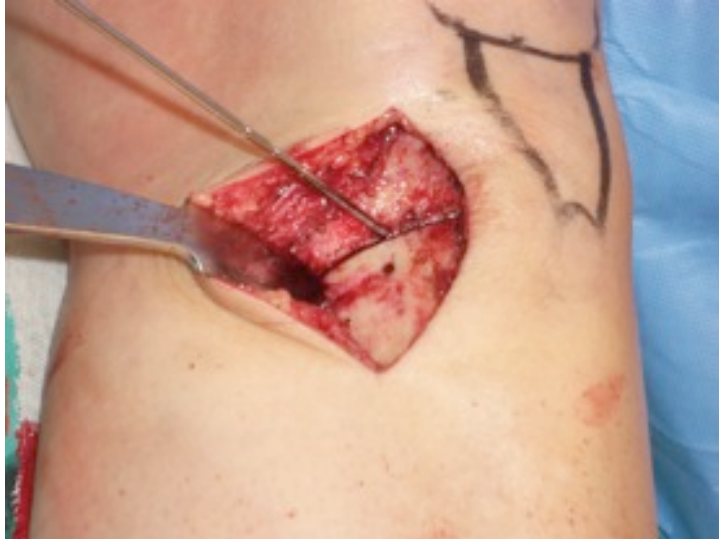

Figure 6: The flexible osteotome is used to perform the osteotomy after the corticotomy is completed with the oscillating saw. It is important that the osteotomy be inferior to the wire to protect from intraarticular fracture.

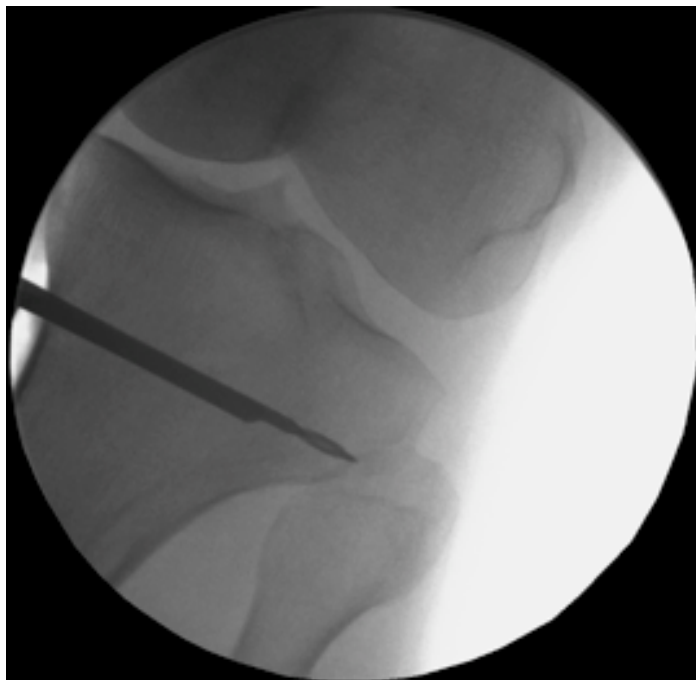

Figure 7a and b: The stackable osteotomes are used. First the wide osteotome is buried after ensuring the cut is complete anteriorly and posteriorly. The narrower osteotome is tapped into place inferior to the wide osteotome until the metaphysis can be hinged open.

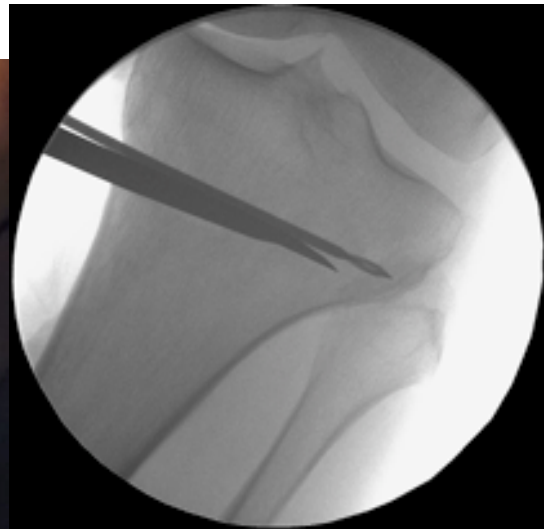
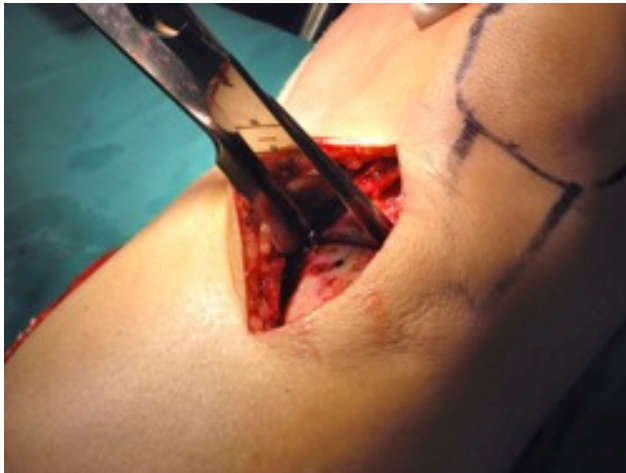
Figure 8a and b: Once the metaphysis can be carefully hinged open a few millimeters the parallel wedges are tapped into place. The size of the opening wedge was determined on the preoperative templating and can be checked using the alignment rod or electrocautery cord as needed.

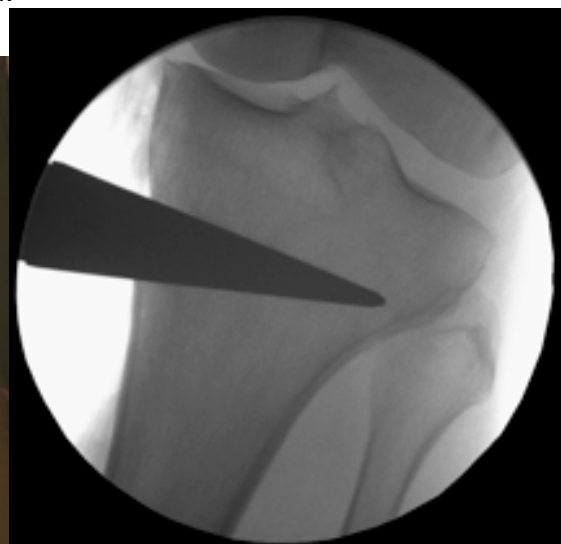
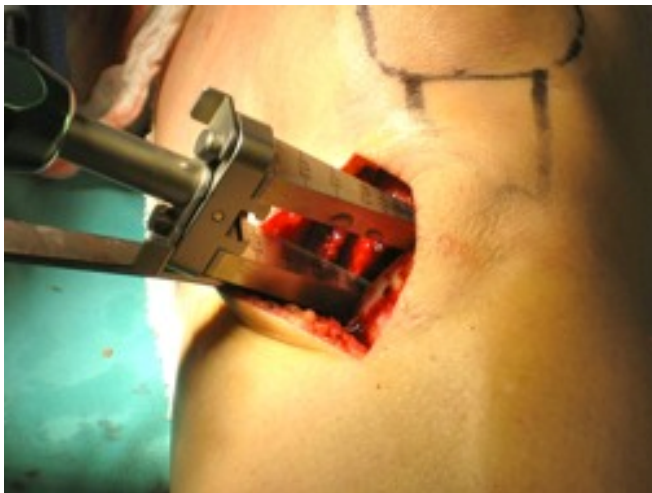

Figure 9: The anterior wedge is removed and the plate with the appropriate sized wedge block is inserted into the osteotomy. Prior to fixation of the plate the surgeon should ensure that the osteotomy opens approximately twice as wide posteriorly as anteriorly. This will ensure the posterior slope of the tibial plateau will remain unchanged.

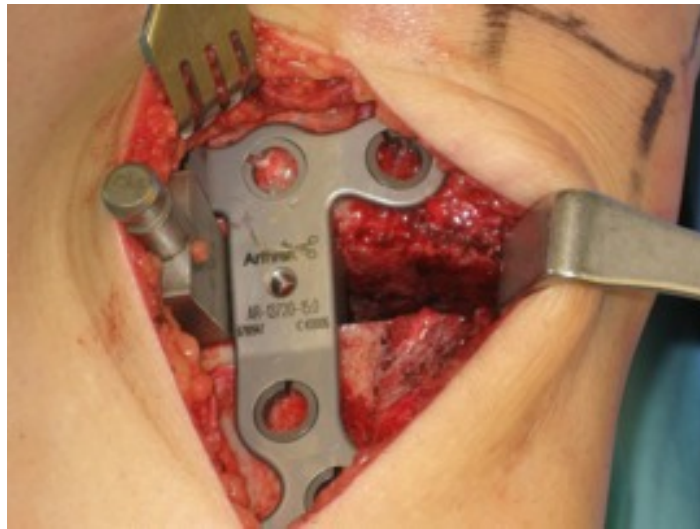

Figure 10a and b: The plate is fixed with locking screws and bone graft substitute has been placed. Final fluoro images demonstrating no hardware complications or joint penetration and no intra-articular fracture.

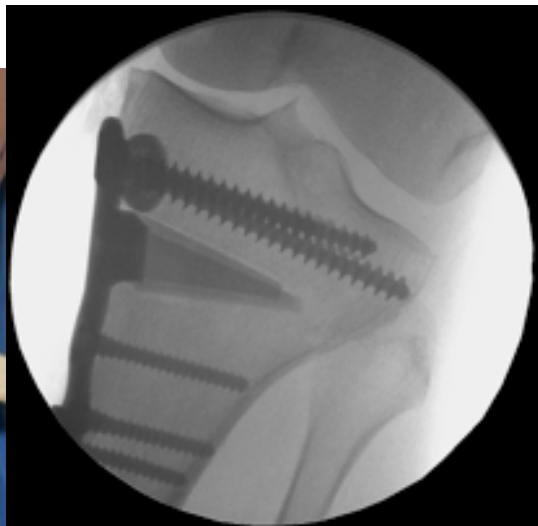
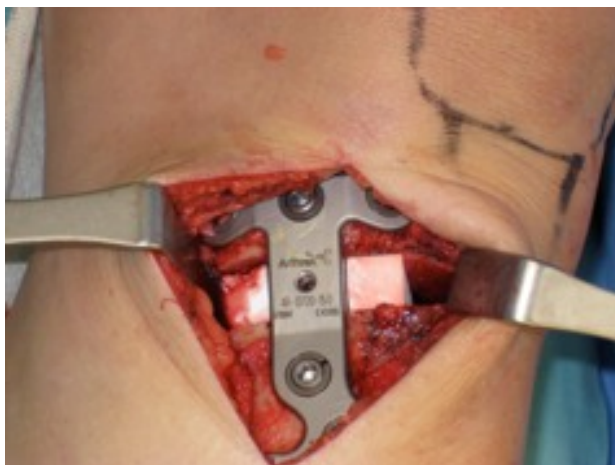


Figure 11: Trackers are shown attached to the tibia and femur for computer navigation

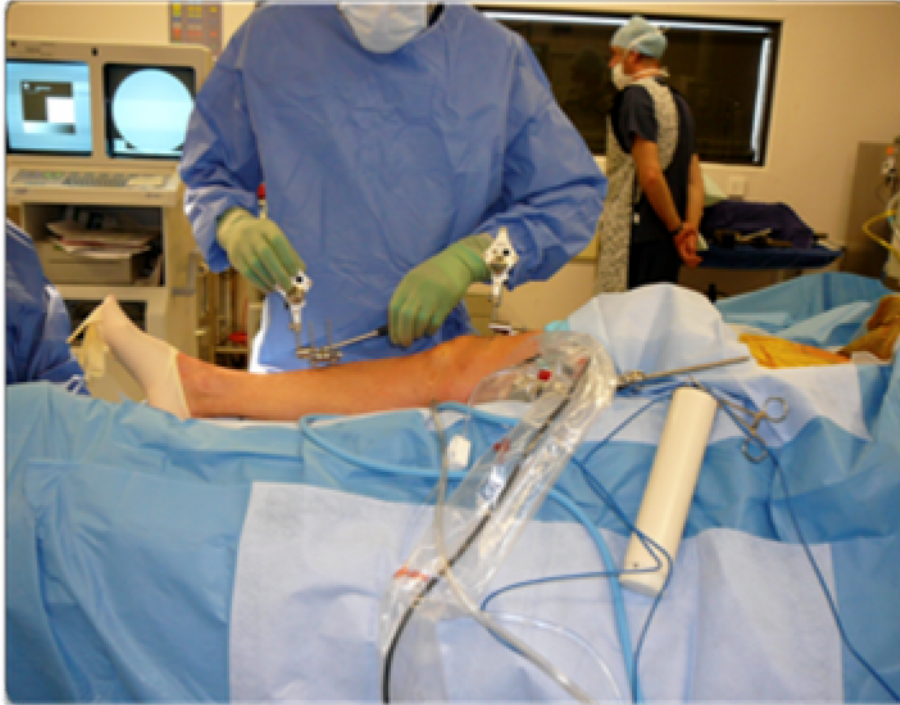

Figure 12: Various points on the limb are registered with the computer. The computer display can be seen behind my head.

